

TASC D Registry

12-month effectiveness analysis of the Pulsar-18 self-expanding nitinol stent in patients with Critical Limb Ischemia (CLI)¹

Conclusions

- Superficial Femoral Artery (SFA) TASC D lesions can be treated with the Pulsar stent with 100% procedural success in CLI patients
- The Average Lesion Length (A.L.L) of 24.5 cm is much longer than other published data^{***} while Primary Patency (PP)* and Freedom from Target Lesion Revascularization (FTLR) rates are similar to this published data²
- In these very long and chronic total occluded lesions the Pulsar stents provide sufficient radial force shown by the 77% PP at 12 months

Study design

Single center, observational study.

Endpoints

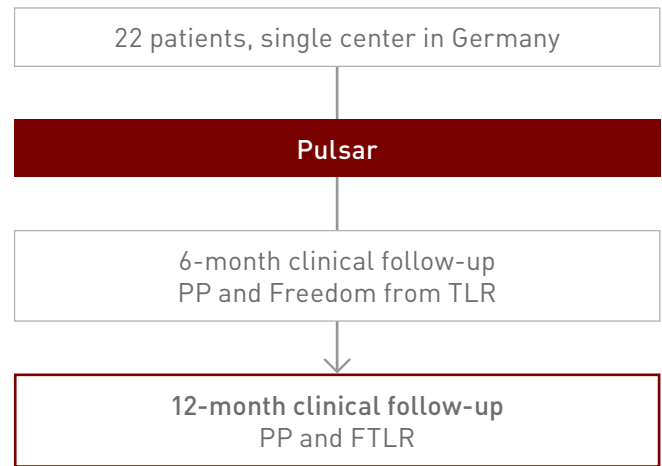
- PP* at 6 and 12 months
- FTLR

Patient characteristics

Patient characteristics	n	%
Average age, yrs	73.8	
Male	9	40.9%
Hypertension	16	72.7%
Dyslipidemia	18	81.6%
Current smoker	10	45.5%
Diabetes mellitus	16	72.7%
Adipositas	15	68.2%
Renal insufficiency	18	81.8%
Rutherford classification 4	17	77.3%
Rutherford classification 5	5	22.7%
Ankle-brachial index (ABI)**	0.44 ± 0.18	

Lesion characteristics

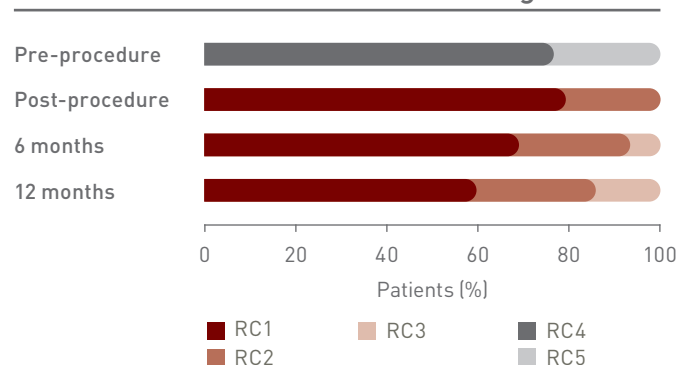
Lesion characteristics	n	%
A.L.L (mm)	245	
Minimal length (mm)	215	
Maximal length (mm)	315	
TASC D lesion with chronic total occlusion >20 cm	22/22	
>1 patent crural vessel	22/22	
Endovascular success with straight line to the forefoot	22/22	



Results

Results	6 months	12 months
PP	86.0%	77.0%
FTLR	91.0%	86.0%
ABI**	0.88 ± 0.2	0.85 ± 0.2

Rutherford Classification (RC) changes



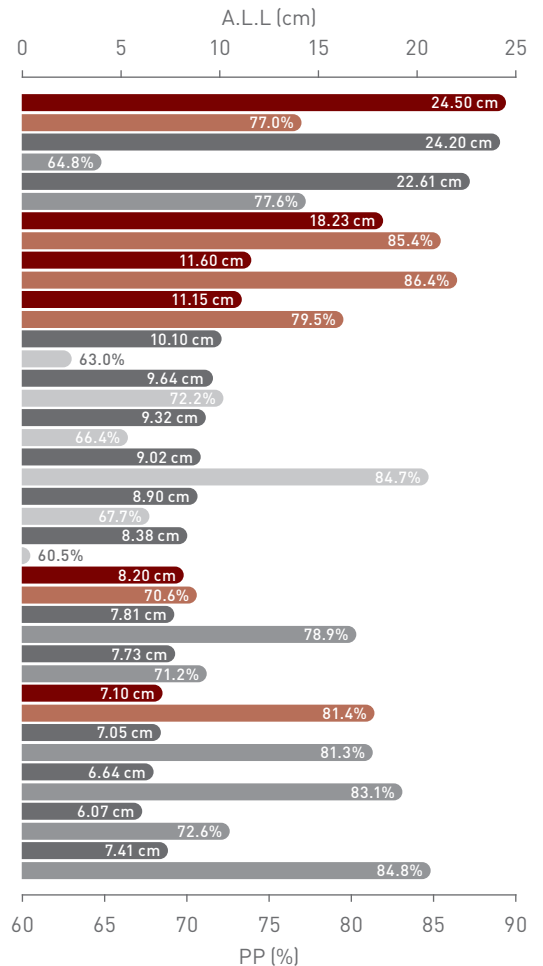
*Restenosis (>50%) on duplex ultrasound

**Data shown as mean ± SD

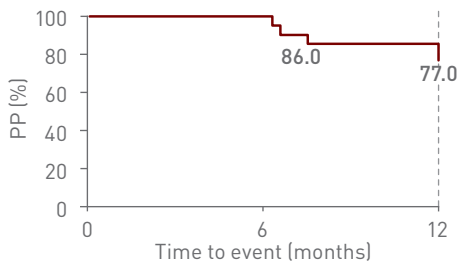
***Check table on the next page with the 12-month clinical results by A.L.L

12-month clinical results by A.L.L

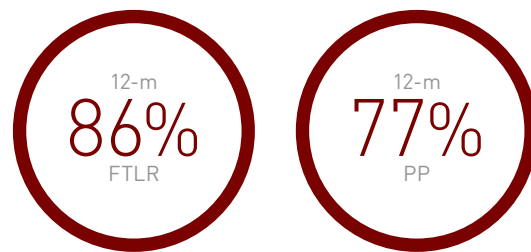
Study	Product	PP	TLR	A.L.L
TASC D ¹	Pulsar	77.0%	14.0%	24.50 cm
DURABILITY 200 ²	EverFlex	64.8%	31.8%	24.20 cm
ZILVER PTX LONG ³	Zilver PTX	77.6%	14.6%	22.61 cm
TASC D II ⁴	Pulsar	85.4%	12.5%	18.23 cm
BIOFLEX PEACE ⁵	Pulsar	86.4%	2.9%	11.60 cm
PEACE ⁶	Pulsar	79.5%	19.0%	11.15 cm
ABSOLUTE ⁷	Absolute	63.0%	n/a	10.10 cm
DURABILITY ⁸	EverFlex	72.2%	20.9%	9.64 cm
SuperNOVA ⁹	Innova	66.4%	14.2%	9.32 cm
SUPERA ¹⁰	Supera	84.7%	n/a	9.02 cm
DURABILITY II ¹¹	EverFlex	67.7%	13.9%	8.90 cm
OSPREY ¹²	Misago	60.5%	13.0%	8.38 cm
BIOFLEX-I ¹³	Pulsar	70.6%	12.4%	8.20 cm
SUPERB ¹⁴	Supera	78.9%	11.1%	7.81 cm
STROLL ¹⁵	S.M.A.R.T. Control	71.2%	12.3%	7.73 cm
4EVER ¹⁶	Pulsar	81.4%	10.7%	7.10 cm
RESILIENT ¹⁷	Lifestent	81.3%	12.7%	7.05 cm
ZILVER PTX ¹⁸	Zilver PTX	83.1%	9.5%	6.64 cm
COMPLETE SE ¹⁹	Complete SE	72.6%	9.4%	6.07 cm
MISAGO 2 ²⁰	Misago	84.8%	10.8%	7.41 cm



12-month PP



Key outcomes



Principal investigator

Dr. Michael Lichtenberg, Klinikum Arnsberg, Germany

1. Lichtenberg M et al. Superficial femoral artery TASC D Registry: twelve-month effectiveness analysis of the Pulsar-18 SE nitinol stent in patients with critical limb ischemia. J Cardiovasc Surg. 2013;54(4):433-9; 2. Bosiers M et al. Results of the Protégé EverFlex 200-mm-long nitinol stent (ev3) in TASC C and D femoropopliteal lesions [DURABILITY 200], J Vasc Surg. 2011;54(4):1042-50; 3. Bosiers M et al. The Zilver PTX Single Arm Study: 12-month results from the TASC C/D lesion subgroup, J Cardiovasc Surg 2013;54:115-22. NCT00120406; 4. Lichtenberg M et al. TASC D II, Evaluation of the 4-French Pulsar-18 Self-expanding Nitinol Stent in Long Femoropopliteal Lesions. Clinical Medicine Insights: Cardiology 2014;8(S2) 37 -42; 5. Lichtenberg M. BIOFLEX PEACE Registry 12 & 24 month results. Presented at: LINC; 2018; Leipzig, Germany; 6. Lichtenberg M et al. PEACE I All-Comers Registry: Patency Evaluation After Implantation of 4-French Pulsar-18 SE Nitinol Stent in Femoropopliteal Lesions. J ENDOVASC THER. 2014; 21: 373-380; 7. Schillinger et al. ABSOLUTE, 12-month results: N Engl J Med 2006;354:1879-88; 8. Bosiers M, Nitinol Stent Implantation in Long Superficial Femoral Artery Lesions: 12-Month Results of the DURABILITY I Study. J ENDOVASC THER 2009;16:261 -269; 9. Powell R et al. Stent Placement in the Superficial Femoral and Proximal Popliteal Arteries with the Innova Self-Expanding Bare Metal Stent System: One- and Two-Year Results of the SuperNOVA Trial. Catheterization and Cardiovascular Interventions 89:1069 -1077 (2017). DOI: 10.1002/ccd.26976; 10. Scheinert D et al. 24-Month Results of the SUPERA SFA Registry, J Endovasc Ther. 2011;18:745 -752; 11. Matsumura JS et al. DURABILITY II 12-month results: J Vasc Surg 2013; 58: 73-83; 12. OSPREY, US Food and Drug Administration, Center for Devices and Radiological Health. Misago® RX Self-expanding Peripheral Stent P140002; 13. BIOFLEX-I, US Food and Drug Administration, Center for Devices and Radiological Health. Pulsar Stent Systems P160025; 14. Garcia L et al. Wire-Interwoven Nitinol Stent Outcome in the Superficial Femoral and Proximal Popliteal Arteries Twelve-Month Results of the SUPERB Trial. Circ Cardiovasc Interv. 2015;8(5). NCT00933270; 15. Gray M D et al. 12-month - STROLL J Vas Interv Radiol 2015;26:21-28 and tctmd 2014 STROLL at 3 years; 16. Bosiers M et al. 4-French -Compatible Endovascular Material is Safe & Effective in the Treatment of Femoropopliteal Occlusive Disease: Results of the 4EVER Trial. J ENDOVASC THER. 2013; 20: 746-756; 17. Laird J R et al. Twelve-Month Results From the RESILIENT Randomized Trial, NCT00673985. Circ Cardiovasc Interv. 2010;3:267-276; 18. Dake M et al. Paclitaxel-Eluting Stents Show Superiority to Balloon Angioplasty and Bare Metal Stents in Femoropopliteal Disease. Twelve-Month Zilver PTX Randomized Study Results. Circ Cardiovasc Interv. 2011;4:495-504; 19. Laird J et al. Nitinol Stent Implantation in the Superficial Femoral Artery and Proximal Popliteal Artery: Twelve-Month Results From the Complete SE Multicenter Trial. J Endovasc Ther. 2014;21:202 -212; 20. Kralj I et al. Three year results of endovascular therapy with a new generation nitinol stent for femoro-popliteal artery lesions - a single-center outcome analysis of a subcohort of MISAGO 2 study. Vasa 2013; 42: 340 - 349.

Pulsar is a trademark or registered trademark of BIOTRONIK and/or its affiliates.